

2014

# Anatomical characterization of the porcine hoof capsule

Meghan Elizabeth Fick  
*Iowa State University*

Follow this and additional works at: <https://lib.dr.iastate.edu/etd>

 Part of the [Veterinary Medicine Commons](#)

## Recommended Citation

Fick, Meghan Elizabeth, "Anatomical characterization of the porcine hoof capsule" (2014). *Graduate Theses and Dissertations*. 14143.  
<https://lib.dr.iastate.edu/etd/14143>

This Thesis is brought to you for free and open access by the Iowa State University Capstones, Theses and Dissertations at Iowa State University Digital Repository. It has been accepted for inclusion in Graduate Theses and Dissertations by an authorized administrator of Iowa State University Digital Repository. For more information, please contact [digirep@iastate.edu](mailto:digirep@iastate.edu).

**Anatomical characterization of the porcine hoof capsule**

by

**Meghan Elizabeth Fick**

A thesis submitted to the graduate faculty  
in partial fulfillment of the requirements for the degree of  
**MASTER OF SCIENCE**

Major: Biomedical Sciences (Anatomy)

Program of Study Committee:  
Eric W. Rowe, Major Professor  
Locke Karriker  
M. Heather Greenlee

Iowa State University

Ames, Iowa

2014

## TABLE OF CONTENTS

	Page
LIST OF FIGURES	iv
LIST OF TABLES	v
ACKNOWLEDGEMENTS	vi
ABSTRACT	vii
CHAPTER 1. INTRODUCTION	1
Background	1
Objectives	2
Thesis Organization	3
References	3
CHAPTER 2. LITERATURE REVIEW	4
Background	4
Profitability	5
Removal of Breeding Sows & Gilts	7
Replacement Gilts	8
Loss Due to Lameness	9
Causes of Lameness	11
Environmental Factors Contributing to Lameness	13
Decreased Productivity	14
Welfare	15
Anatomy of the Distal Limb	16
Distal Limb Osteology	17
The Digital Organ	18
Segments of the Hoof	20
Epidermis	22
Dermal-Epidermal Junction	22
Comparative Anatomy	24
Current Therapies	24
References	25

CHAPTER 3. GROSS ANATOMICAL MEASUREMENTS AND MICROSCOPIC QUANTIFICATION OF EPIDERMAL LAMINAR DENSITY OF THE PORCINE HOOF CAPSULE	30
Abstract	30
Introduction	31
Materials and Methods	33
Measurement of Hoof Wall Dimensions	33
Quantification of Epidermal Laminae	34
Statistical Analysis	36
Results	36
Hoof Wall Measurements	36
Dorsal Wall Length	36
Abaxial Wall Height	36
Sole Width	37
Sole + Wall Length	37
Ground Surface	38
Dorsal Wall Depth	39
Abaxial Wall Depth	39
Sole Depth	39
Dorsal Wall Depth vs. Abaxial Wall Depth	40
Dorsal Wall Depth vs. Sole Depth	41
Sole Depth vs. Abaxial Wall Depth	42
Quantification of Epidermal Laminae	42
Thoracic Limb Zone Width	42
Pelvic Limb Zone Width	43
Thoracic vs. Pelvic Limb Zone Width	43
Thoracic Limb Branching	44
Pelvic Limb Branching	44
Discussion	44
References	47
Figures & Tables	50
CHAPTER 4. GENERAL CONCLUSIONS	55

## LIST OF FIGURES

	Page
Figure 1. Location of sole depth measurements	51
Figure 2. Schematization of hoof wall measurements as seen from the lateral aspect of the digit	51
Figure 3. Schematization of hoof wall measurements as seen from the ground surface (volar) aspect of the digit	52
Figure 4. Example of use of plywood and cable ties to manipulate the distal limb into an assumed weight bearing position as seen from the plantar-lateral aspect	52
Figure 5. Schematization of hoof slices used to quantify epidermal laminae	53
Figure 6. Schematic diagram of a hoof slice divided into zones of 25 laminae each	53

## LIST OF TABLES

	Page
Table 1. Mean and standard deviation of hoof wall and sole measurements	54
Table 2. Mean and standard deviation of hoof wall and sole depths	54
Table 3. Mean measurements of epidermal laminar zone width	55

## ACKNOWLEDGEMENTS

I would like to thank my committee chair, Dr. Eric Rowe for his time, mentorship and support throughout the course of my four years of veterinary school and this research project. I would also like to thank my committee members, Dr. Locke Karriker and Dr. Heather Greenlee for their guidance and contributions.

In addition, I would like to thank my classmates and professors at Iowa State University for enabling me to work on this degree while concurrently finishing my DVM. I want to also offer my appreciation to my colleagues and mentors at the University of Wisconsin- Madison School of Veterinary Medicine for allowing me time to travel to Iowa, finish my research, as well as write and defend this thesis all while fulfilling my duties as a small animal rotating intern.

Finally, thanks to my friends and family for their endless patience and encouragement, without whom this would not have been possible.

## ABSTRACT

One of the leading causes of involuntary culling of breeding stock in swine is lameness. Many of these sows are lame due to lesions of the hoof wall. Although an important function of the porcine hoof capsule is to protect the terminal limb structures, little is known about its anatomy. The purpose of this study was to create a basic reference for normal porcine hoof measurements as well as quantify the density of epidermal laminae.

For the hoof wall measurements, forty forelimbs and forty hind limbs were obtained from clinically sound sows and sixty-nine forelimbs and seventy-four hind limbs were obtained for the second part of the study. For the hoof wall, measurements were made investigating the dorsal wall length, abaxial wall height, sole width, sole + wall length, ground surface, dorsal wall depth, abaxial wall depth and the sole depth at the cranial, caudal, axial and abaxial aspects. The second group of limbs were sliced for visualization of the laminar junction. The laminae were stained and divided into zones of 25 laminae each.

Significant differences were present between the dorsal wall depth and the abaxial wall depth of various digits, but the sole depth at all four measurements (cranial, caudal, axial, abaxial) was significantly thicker than the abaxial wall depth on all eight measured digits ( $p < 0.0001$ ). The laminae also showed significant decreases in zone width as they moved from the palmar/plantar aspect of the hoof to the dorsal aspect with zones A and B being significantly smaller than all of the other zones on both the thoracic and pelvic limb ( $p < 0.0001$ ).



These results demonstrate that the thinnest measured location of the hoof wall is the abaxial wall. The abaxial wall wall depth is significantly less than the depth of the hoof at the location of the sole, or in many digits, the dorsal wall as well. The abaxial wall region also holds the least dense zones of epidermal laminae, with the density increasing at the more dorsal aspect. With the thinnest wall and the sparsest laminae, the inherent anatomy of this region is likely to play a role in the frequency of lesions reported in this location.

## CHAPTER 1. INTRODUCTION

### Background

The efficiency of the swine industry depends on sow productivity and longevity. Producers, veterinarians and barn workers alike have similar aims, to ensure that resources are used efficiently and sows are not culled before the length of their natural productive life. A sow's productivity is measured by the amount of pigs she weans and are sold in her lifetime (Stalder 2012). The importance of sow longevity is evident when considering replacement. Poor sow longevity is associated with more replacement gilts, costing producers more than just the associated cost with the initial purchase. Replacement gilts have a higher disease risk accompanying them, they produce less piglets and their first litter often has poorer performance.

Culling accounts for higher percentages of sow removal than euthanasia or natural death. Lameness has historically been one of the top three causes of early removal in the breeding herd along with reproductive failure and old age. Lame sows not only have a higher chance of being culled before they pay for themselves, but they also will not attain ideal breeding efficiency (Anil et al. 2005). Commonly identified causes of lameness in breeding sows include musculoskeletal diseases and foot lesions (Schenck 2010). Recently, more emphasis has been put investigating the effects of foot lesions on productivity and efficiency. While both environment and genetics have been shown to play a role in sow longevity, the responsibility of the inherent anatomy of the hoof capsule has not been investigated.

Little research has been done on the porcine distal limb, and most of the assumed information has been extrapolated from studies on equine and bovine hooves. Anatomical investigation of the porcine hoof capsule can give producers a basis for lameness assessment and scoring and the possibility of implementing hoof trimming techniques with goals of prevention.

### Objectives

The overall goal of this project was to identify normal values of hoof wall measurements of the porcine digit. The dermal-epidermal junction was also evaluated to investigate the laminar density of the dorsal aspect of the digit when compared to the axial and abaxial walls toward the palmar/plantar surface. The central hypothesis was that there would be variability between the measurements of the lateral and medial digits of the hind limb, specifically the thickness of the abaxial wall region when compared to that of the wall at other regions. It was also hypothesized that the laminae would be less dense in the abaxial wall region. This hypothesis was based on existing reports of frequency and location of foot lesions in the porcine hoof wall at these specific locations.

The long-term goal is to provide swine producers with normal values with the hopes of implementing hoof trimming standards and a shift towards preventative measures. Producers, consumers and veterinarians equally would benefit from lower culling and replacement rates; as well as healthier breeding sows and improved animal welfare.

## Thesis Organization

This research-based thesis begins with a literature review relative to current swine production systems, the economic impact and related inefficiency of culling the breeding stock, causes of culling, lameness in sows and the anatomy of the distal limb. Second, the manuscript includes a brief introduction, and the study design and results are described in greater detail. Manuscript authors played a role in acquiring, storing and preparing the specimen for measurements, and preparation of the manuscript. Conclusions and references will conclude the thesis.

## References

- Anil, Sukumarannair S., Leena Anil, and John Deen. 2005. "Evaluation of patterns of removal and associations among culling because of lameness and sow productivity traits in swine breeding herds." *Journal of the American Veterinary Medical Association* 226: 956-961.
- Schenk, Erin L., Jeremy N. Marchant-Forde and Donald C. Lay Jr. 2010. "USDA Sow Lameness and Longevity." *USDA Sow Welfare Fact Sheet: Livestock Behavior Research Unit*.
- Stalder, Kenneth, Sylvie D'Allaire, Richard Drolet and Caitlyn Abell. "Longevity in Breeding Animals," in *Diseases of Swine*, ed. Jeffrey J. Zimmerman, Locke A. Karrow, Alejandro Ramirez, Kent J. Schwartz and Gregory W. Stevenson, (Ames: Wiley-Blackwell, 2012), 50-59.

## CHAPTER 2. LITERATURE REVIEW

As the swine industry continues to deal with increased competition for feed and resources, not just in the Midwest, but across the United States, the matter of maintaining efficient use of resources becomes increasingly important. Retaining healthy breeding stock (sows, gilts and boars) is a vital component in avoiding unnecessary losses, reduced efficiency and incurring unwanted costs. Currently one of the leading causes of culling breeding stock earlier than the end of their natural productive lifespan is lameness. Little research has been done into the anatomical variations of the sow hoof, as well as the added environmental factors that could play a role in this dilemma. The role of veterinarians in the swine industry has shifted over time from the treatment of individuals with disease to evaluation of the herd as a whole. Intense focus is now being put on disease prevention and vaccination strategies to maintain healthy herds. In order to fully understand swine lameness and formulate treatment or preventative plans, it is important to investigate the anatomical factors playing a role.

### Background

The September 2014 United States Department of Agriculture (USDA) inventory of all hogs and pigs in the United States was 65.4 million head, with the breeding inventory at 5.92 million head (Quarterly Hogs & Pigs 2014). Although the Midwest is known as the major swine-producing region of the United States, swine operations can now be found in all 50 states (Gillespie and Flanders 2009). Iowa and

North Carolina are leading the nation in the number of swine operations. Nationwide, the number of large operations (greater than 5,000 head) has been on an upward trend, while the number of small to medium hog operations (less than 5,000 head) has been declining (U.S. Hog Breeding Herd Structure 2006), (Overview of the US Hog Industry 2012), (McBride and Key 2013).

Throughout the last three decades the productivity of the hog-breeding herd has steadily increased. Overall herd health has improved with better disease prevention and management, superior environmental conditions and facilities, as well as genetic selection for productivity traits, all of which contribute to the increased average number of animals per breeding herd. Genetic selection has been focused on traits such as growth rate, lean body mass, and feed conversion rates, as well as some reproductive factors like farrowing rate, number of piglets born alive, pre-weaning mortality and sow longevity (Fitzgerald et al. 2012), (Serenius and Stalder 2006). All of these improvements can be reflected in the number of litters per sow each year and increasing litter sizes (U.S. Hog Breeding Herd Structure 2006), (Overview of the US Hog Industry 2012). The June-August 2014 quarter pig crop had decreased 1% from 2013 with average litter sizes dropping to 10.16 after reaching an all time high of 10.33 piglets per litter in 2013 (Quarterly Hogs & Pigs 2014).

### Profitability

As the swine industry continues to grow, it is important to maintain efficiency leading to productivity. Efficiency in the swine industry goes hand in hand

with maintaining welfare. This balance must occur in all phases of production. Two main factors contributing to profitability are feed efficiency of the finishers and the number of pigs weaned per sow each year (Gillespie and Flanders 2009). Since approximately 10% of the nations total hogs are kept back for breeding, the profit comes from the other 90% that are sent to market (Quarterly Hogs & Pigs 2014). Recently, the United States has been dealing with the porcine epidemic diarrhea virus (PEDv). This coronavirus, similar to transmissible gastroenteritis virus (TGE), is transmitted through the fecal-oral route and mostly affects piglets (Porcine Epidemic Diarrhea 2013). Although the full economic impact of PEDv has not been thoroughly evaluated yet, it is estimated that early in 2014, the United States had lost around 5 million piglets. That immense loss means that there will be a decreased number of hogs going to market, approximately 3% less than last year. (Hill et al. 2014).

In the sow herd, profit comes from a combined total of the number of pigs weaned per litter and the number of litters per breeding female each year (Zimmerman et al. 2012). This measure of reproductive performance begins with the total number of live piglets at farrowing and those that survive the preweaning phase. On average, over 90% of piglets are born alive and preweaning mortality generally ranges between 10-20% (Zimmerman et al. 2012), (Swine 2006: Part III 2008). Most of these deaths, occurring either at farrowing or within the first five days of life, are caused by trauma from the sow or low viability due to starvation (Gillespie and Flanders 2009), (Swine 2006: Part 1 2007), (Swine 2006: Part III 2008), (Nielsen et al. 2013). In order to be sold at market, these pigs must also

survive the nursery and finishing phases. Deaths in nursery age pigs are generally low, at less than 5%, from varying causes. Finishers also account for a small number of profit losses with approximately a 6% death rate. Of the losses in the finishing herd, lameness is generally one of the three most commonly producer identified causes for culling, behind respiratory and gastrointestinal problems. (Swine 2006: Part 1 2007), (Swine 2006: Part III 2008).

### Removal of Breeding Sows & Gilts

One of the major economic losses experienced by producers is the early removal of breeding stock. Animals are removed from the herd by culling, euthanasia or natural death. Herds with high death or euthanasia counts will encounter some of the greatest losses per sow (Zimmerman et al. 2012). In 2006, the average percentage of sow deaths per year in the United States was 8.84% (Anil et al. 2007). Voluntary removal, usually planned due to old age, inadequate performance or small, less viable litters, creates less economic disparity since the producer has prepared for it (Zimmerman et al. 2012). Sow death often occurs right around farrowing, so the lack of income associated with litters, the income that would have been associated with sale for slaughter, plus any veterinary costs make these type of losses extremely unfavorable (Zimmerman et al. 2012), (Anil et al. 2005). Breeding sows are the most valuable animals in the swine industry, so measuring sow longevity is important when assessing a herd. The length of time a sow is productive will determine not only how profitable she is, but also the cost of her offspring. Culling younger sows from the herd will only increase the cost of each



weaned pig (Anil et al. 2009). According to the USDA and other sources, approximately 50% of the sow and gilt inventory are culled each year for various reasons (Schenk et al. 2010), (Anil et al. 2007). This number was higher at large sites versus small or medium sized sites (Swine 2006: Part 1 2007). It is important for effective culling strategies to be implemented in all swine operations.

### Replacement gilts

As older sows are culled, new replacement gilts are brought in. Voluntary culling allows for better planning of replacement animals (Zimmerman et al. 2012). Overall the average parity for sows at culling is 3, with over 50% of sows being culled by the fourth litter (Schenk et al. 2010). A good balance of older sows and new gilts is necessary. Herds with high replacement rates will have a higher proportion of new gilts compared to those with low replacement rates, which will show a larger pool of older females. A herd with a higher percentage of gilts will have lower productivity due to the higher piglet mortality rates, reduced growth and more non-productive days than older sows. However, a herd with a higher percentage of older sows could also have problems since older sows are more prone to disease and can have lower production levels (Zimmerman et al. 2012). Although there are many factors influencing the removal rate, it is generally more common to see herds with high removal rates and lower productivity due to the replacement gilts.

Unfortunately, the cost of replacing gilts is a reality that all hog producers face. Some choose to raise their own replacement gilts, which may offset some of the

cost, but additional facilities are required. Other operations choose to purchase their replacement gilts, choosing breeding stock from programs that have been genetically improved by continued performance testing of the boars and sows. The ability to buy better breeding stock will cost more initially, but will have better returns at market (Gillespie and Flanders 2009). Producers that do not replace the breeding stock will have herds with decreased productive days eventually affecting sow output (Schenk et al. 2010).

Breeding herds with lower removal rates will have decreased economic losses by minimizing the amount spent on replacement gilts and increasing the sow output (Schenk et al. 2010). In general, gilts are less productive than older sows. So culling sows for reasons other than reproductive failure will lead to smaller litters, poorer feed efficiency in the nursery and finisher phases, and greater mortality in the pre-weaning phase (Schenk et al. 2010).

#### Loss due to lameness

Historically, lameness has been one of the major reasons for involuntary, or unplanned, culling of sows. In a 2006 study on causes for culling; lameness was one of the top 3 reasons, following reproductive failure and performance (Swine 2006: Part 1 2007). Of all the swine operations surveyed, lameness accounted for approximately 15% of culled breeding-age females in the United States (Swine 2006: Part III 2008), (Schenk et al. 2010). Reproductive failure accounted for 36.9% and performance, which included small litter size, high preweaning mortality or low birth weight, comprised 23.7% (Zimmerman et al. 2012), (Swine 2006: Part III

2008). Some sows, as many as 25% in one report, which are removed from the herd for lameness must be euthanized for welfare reasons. This results in even more of a financial loss due to the direct loss of the sow (Zimmerman et al. 2012). Both reproductive failure and decreased performance can be consequences of lameness, meaning that the incidence of culling lame sows is most likely underreported. Another study, evaluating the accuracy of farm personnel in sow culling classifications showed that many times recorded culling classifications were inaccurate (Knaur et al. 2007). In a 1989 estimate, the calculated economic loss due to sow herd lameness in the United States alone was over \$24 million (Schenk et al. 2010). Due to the age of this information, the overall economic impact is likely greater today. Another estimate took multiple costs into account, like culling costs, increased veterinary care, replacement costs and costs associated with higher pre-weaning mortality and lower piglet viability and found that just one lame sow can cost producers anywhere from \$181-\$422 once diagnosed with a foot-related problem (National Hog Farmer 2010).

Although the overall average parity for culled sows is between 3-4, some studies show that most of the breeding herd culled due to lameness are either gilts or first parity sows (Zimmerman et al. 2012), while older sows are more likely to be culled due to inadequate performance. Since young females are culled close to the initial investment, which is early in their expected life, there is a greater negative effect on the productivity of the herd (Anil et al. 2005). However, a second study showed that sows culled for lameness were older, on their second or third parity because those with reproductive failure had already been culled at a young age (Anil

et al. 2005). In order for the producer to earn back the initial investment of a sow, she must reach her third or fourth parity. This results in many lame sows being removed from the herd before they are economically productive (National Hog Farmer 2010).

### Causes of lameness

The most common causes of lameness driving culling of breeding age swine are musculoskeletal diseases and foot lesions. Cartilage integrity, as found in diseases such as osteochondrosis, osteoarthritis and arthritis, can deteriorate and cause lameness in growing and breeding stock. Other swine are seen with foot rot, injuries or fractures (Schenk et al. 2010). Although foot lesions are not the most common cause of lameness in sows, many sows culled for lameness will have an obvious primary lesion, and then a less obvious secondary lesion. In one study, the most common post mortem foot lesion seen were overgrown claws, torn dewclaws, hoof cracks or sole ulcers (Dewey et al. 1993). Younger sows are less prone to foot problems, as older sows have spent more time on improper flooring throughout their life. It is important to note that all sows with foot lesions are not necessarily lame. In one experiment with 223 sows, only 144 had hoof lesions and merely 11.8% of those were severe lesions and 41.0% were moderate lesions (Fitzgerald et al. 2012). Two important factors to take into consideration for the cause of foot lesions are feeding systems and the housing. Group housed sows fed individually in feeding stalls have been shown to have less injuries and more longevity than those fed individually with electronic feeders (Schenk et al. 2010). Lameness has been

attributed to changes in sow behavior around feeding time. Two different studies have shown that sows with overgrown hooves are unwilling to spend a normal amount of time standing and feeding. With these sows, there is an increased chance for slipping and more attempts at rising. This overall decreased time spent bearing weight is just one of the signs of discomfort shown (Zimmerman et al. 2012).

In most reports, sows are more likely to have lesions and overgrowth in the hind limbs, with the lateral hoof being longer than the medial (Fitzgerald et al. 2012). As animals become increasingly lame, the weight distribution shifts from the painful digit to other limbs or digits. This could lead to additional injuries and lesions in previously non-affected hooves. In swine, pressure studies have shown that in the front limbs, the medial digits have the highest stress. These same studies showed the opposite in the hind limbs; with the lateral digits under more stress and often times most lesions are localized to the lateral claw (Ciaco de Carvalho et al. 2009), (Fitzgerald et al. 2012). When comparing the front limb to the hind limbs; the lateral rear digits are overstressed compared to the medial digits, as the weight is not evenly distributed. In the forelimbs, the weight is more evenly distributed between the two digits. Although the forelimbs bear more weight overall, the difference in pressure patterns between the lateral and medial digits is much more significant in the hind limb, possibly explaining the higher reports of foot lesions in the hind limb (Ciaco de Carvalho et al. 2009), (Sun et al. 2011).

## Environmental factors contributing to lameness

Housing systems can also influence the amount of injury and trauma inflicted on the foot. Commercial swine production facilities are typically classified according to the type of housing; pasture systems, a combination of pasture and low-investment housing and total confinement systems (Gillespie and Flanders 2009). Throughout the four production phases, total confinement is the most common type of facility. Most hogs will live in total confinement throughout their lives (Swine 2006: Part 1 2007). In general there are three types of floors used in hog facilities, solid surfaces, partial slats and complete slats (Gillespie and Flanders 2009). Almost half of all operations participating in a 2006 study by the USDA had completely slatted flooring. Solid surfaces and partial slats made up the rest of the majority with dirt comprising a small percentage (Swine 2006: Part 1 2007). Flooring material is based on cost, labor required and the production phase. Both solid floors and those with partial slats, although less expensive, require regular cleaning and hogs will spend more time standing in manure. Complete slats can be obtained in metal, concrete, fiberglass and plastic (Gillespie and Flanders 2009). Over 94% of the slatted flooring material during the gestation and finisher phases was concrete, while metal was used for farrowing. The nursery phase was divided more evenly between concrete, metal and plastic materials (Swine 2006: Part 1 2007).

The two most popular housing options during the gestation phase for breeding sows are totally confined gestation crates, which are individual crates with partially slatted floors or group pens within hoop structures with deep bedding.

One study shows that sows housed in the more natural hoop structures had shorter wean-to-breed intervals, lower preweaning mortality, and more piglets born alive. The cull rate of the sows housed in group pens was also lower than those held in individual gestation crates (Honeyman and Johnson 2002). The current animal welfare trend is shifting gestation housing into a more natural; group oriented setting over the concrete or metal gestation crates. Although there are benefits to the hoop type group housing, this can also increase the likelihood of injuries, especially to the claws, due to aggression between sows and the increased mobility (Anil et al. 2009).

#### Decreased productivity

Lame sows have reportedly fewer litters and higher preweaning mortality than non-lame sows. Multiple studies have shown sows with overgrown hooves will produce smaller litter sizes (Fitzgerald et al. 2012). This may be due to the fact that sows with hoof lesions spend less time standing and eating while in lactation and this can reduce subsequent litter sizes and reproductive performance (Zimmerman et al. 2012), (Fitzgerald et al. 2012), (Knaur et al 2012). Sows with foot lesions, such as cracked hooves and differences in the length of their medial and lateral claws, have increased piglet mortality during lactation and generally produce fewer piglets per litter (Fitzgerald et al. 2012). Since they are not able to move about as easily due to the pain associated with the likely inflammation, most sows are not willing to spend as much time feeding or standing (Fitzgerald et al. 2012). If this lack of adequate feed intake occurs during lactation, this can affect not only her future

reproductive performance, but also the viability of the piglets (Anil et al. 2009). Piglet mortality will increase as the lame sow has more difficulty moving around the farrowing crate and the chance of crushing may be increased. Not only are these lame sows a financial burden in productivity loss and replacement costs, but also they are likely to have decreased value at market (Anil et al. 2009).

## Welfare

Economics are a vital component of the swine industry, and profitability is directly related to animal welfare in the management of a successful swine operation. Poor sow longevity can be detrimental and inefficient economically as well as causing animal welfare concerns. Pain, either acute or chronic, can alter normal swine behavior. The sensation of pain is a complex process from multiple nerve cells, neurotransmitters and nerve cell receptors before generating the signal to the central nervous system. The International Association for the Study of Pain has stated that pain is “an unpleasant sensory and emotional experience” and that “the inability to communicate verbally does not negate the possibility that an individual is experiencing pain” (Zimmerman et al. 2012). Chronic pain does not necessarily correlate to a particular injury, but more often is associated with prolonged inflammation from damaged tissues (Zimmerman et al. 2012).

Whether the operation is a small, family farm or a large corporation based type of facility, the Farm Animal Welfare Council has named the “five freedoms” that serve as a guideline for farm animal welfare programs across the world (Zimmerman et al. 2012). These five freedoms focus on three areas: “biological



functioning”, “nature-based” and “feeling-based.” (Zimmerman et al. 2012) These areas look at fitness and health, behavior under natural conditions and fear and distress. Of these five freedoms, the third freedom specifically, the “freedom from pain, injury, and disease by prevention or rapid diagnosis and treatment” comes most into play with the diagnosis of lameness (Zimmerman et al. 2012). Not only is this a problem causing swine operations profit losses by early replacement of the breeding stock but it is an animal welfare issue as well.

Diagnosing lameness in swine can be difficult and unrewarding. Physical exams and evaluation of the musculoskeletal system can be near impossible to perform. Lameness is most often an ante mortem diagnosis by observing the sow’s gait, with the exact cause being determined at necropsy (Dewey et al. 1993).

Lame sows are a financial burden on swine producers, whether losing money directly by being culled early and then replaced by less productive gilts or whether their lameness is causing pain that decreases their own productivity. Reducing the rate of lameness would increase the parity of the herd as well as the increased benefits such as larger litter sizes and an increased farrowing rate. Foot lesions have been found to be one of the top causes of lameness in older sows, but little research has been done as to investigate the anatomy of the pig foot, more specifically the hoof capsule, itself.

#### Anatomy of the Distal Limb

Over the course of time, the distal limb has evolved among species. Initially, all mammals had the five digits that can still be seen on the human hand. Each digit

is part of a complete ray, which consists of the metacarpal or metatarsal bone and the associated phalanges. The first, most medial ray is evolutionarily the first to disappear, leaving only rays two through five complete, like in the pig. Next, the second ray or most lateral fifth ray would become absent, such as in the ruminant. Finally, equine species exhibit the highest degree of ray reduction with only the third complete ray being completely retained. Furthermore, mammals can be classified according to their foot posture, plantigrade, digitigrade or unguligrade. Plantigrades, like primates and humans, have their entire distal limb (phalanges, metacarpals/metatarsals and carpal/tarsal bones) in contact with the ground. Digitigrades, like dogs and cats, bear weight on the digits only (proximal, middle and distal phalanx), and unguligrades, pigs, ruminants and horses for example, only contact the ground with the extreme distal most aspect of the limb, the distal phalanx (Nickel et al. 1986).

#### Distal limb osteology

The equine distal limb has had the most modification of domestic species. There has been complete regression of the first and fifth rays and reduction of the second and fourth, so only the third ray remains completely developed. The small second and fourth metacarpal/metatarsal bones can be found on either side of the large third metacarpal/metatarsal bone, which is commonly referred to as the cannon bone (Nickel et al. 1986), (Nickel et al. 1981). Ruminants and pigs have four digits, two through five. In the ruminants there are two weight bearing digits, three and four, and two dewclaws, two and five. The second and fifth digits, accessory

digits, are rudimentary, lacking complete metacarpal/metatarsal bones and are less functional not contacting the ground (Nickel et al. 1981). The pig has four rays present, two through five, with the first digit being absent. Like the ruminant, the third and fourth digits are the weight bearing digits with the second and fifth being referred to as dewclaws. In the pig, the dewclaws are not rudimentary, and contain the necessary phalanges, metacarpals/metatarsals and sesamoids to be considered a complete ray (Sisson et al. 1975). The third digit is the more medial of the weight bearing digits while the fourth is located laterally. The third and fourth digits are longer and thicker. The second and fifth are smaller, but similar. The dewclaws only bear weight on soft ground (Nickel et al. 1981). Each digit is made up of three main bones; the proximal, middle and distal phalanges and the three sesamoids. The two proximal sesamoids, axial and abaxial sesamoids, are located at the metacarpophalangeal joint and the distal sesamoid is associated with the distal interphalangeal joint (Nickel et al. 1981).

Reducing the number of rays in the distal extremity makes it easier to raise the limb off of the ground by reducing the weight bearing surface and therefore the associated friction as well (Nickel et al. 1986). This regression of rays increases the weight distribution to each digit, necessitating the development of the digital organ (Nickel et al. 1986).

#### The digital organ

The hoof is a highly keratinized epidermis that functions in protecting the terminal limb structures in ungulates. It is analogous to finger nails in primates or

claws in carnivores. Along with the distal phalanx, or P3, and the distal portion of the middle phalanx, the distal sesamoid bone and flexor and extensor tendons are enclosed in the hoof. This digital organ is not only protective of the phalanges, but it can also be used as a tool for scratching and digging or even as a weapon in some species. (Nickel et al. 1981), (König et al. 2007). Ungulates, like horses, ruminants and swine, are generally classified as a group of animals that use the distal phalanx to bear all of their weight. This means another function of the hoof is shock absorption.

In species with more than one complete ray, the terms axial and abaxial must be used to describe opposing surfaces. Axial is used to describe the axis of rotation, or midline, and abaxial faces away from the axis. In general the two hooves on one limb are almost mirror images. The axial surface of the hoof wall is concave while the abaxial surface is convex (Frandsen et al. 2009).

The digital organ consists of a keratinized epidermis, the dermis and hypodermis as well as the bones, subcutis and other structures. In ungulates, the epidermis is a continuation of the skin that is made of a hard keratin layer overlying the vascular dermis (Monteiro-Riviere et al. 1993). Keratin is one of the main proteins found in the hoof, as well as the skin, hair, claws, nails, feathers, wool, and horns. Keratins can either be classified as soft, like those in skin, or hard, like those in hoof and horn (Pollitt 2004). The modified epidermis consists of a stratified squamous epithelium that makes up the three main parts of the hoof; the wall, the sole and the heel. The dermis, or corium, is a connective tissue layer that contains blood vessels and nerves and blends with the periosteum of the distal phalanx. A

tight connection is necessary between the epidermis and the corium for nourishment, the increased weight bearing load at the area of the junction of the heel and abaxial wall, as well as efficient weight transfer and distribution between digits (Nickel et al. 1981) (Anil, L. et al. 2007). The bulb of the heel is the only region with the subcutis present. This additional structure, composed of adipose and connective tissues, functions as a shock absorber (König et al. 2007).

### Segments of the hoof

Much like the claw and nail, there are five segments that comprise the hoof capsule of all ungulates. Research into these components of the hoof has predominantly been done in the horse. Due to a general lack of knowledge on the porcine digital organ, it has been assumed that this information is also applicable to the pig. The dorsal, axial and abaxial hoof wall is made up of three of these segments; the perioplic segment (stratum externum), the coronary segment (stratum medium), and the parietal segment (stratum internum). Along with the distal portion of this hoof wall, the fourth and fifth segments, the sole and the footpad (also referred to as the bulb or heel), make up the ground surface. Although these segments are distinguishable in all ungulates, the characteristic features vary between species (König et al. 2007).

The periople is a thin waxy layer of tubular and intertubular horn on the outside of the hoof adjacent to the haired skin. The coronary segment also consists of tubular and intertubular horn and arises from a portion of epidermis at the coronary band. The coronary band is the region where haired skin becomes hoof

wall (Frandsen et al. 2009). The tubules are circularly arranged cells formed parallel to the dorsal hoof wall. The spaces between the tubules are filled with intertubular horn (Monteiro-Riviere et al. 1993). The parietal horn, or the wall segment, is the also known as the stratum internum. This layer is continuous with the stratum medium, and projects sheets (laminae) of stratum corneum to interdigitate with similar dermal laminae.

The sole occupies the anterior portion of the ground surface of the hoof. It forms a flat surface that along with the bulbar segment (foot pad or heel) constitutes the weight-bearing surface. Like the periople and coronet, the sole is composed of tubular and intertubular horn. In swine, the keratinization of the sole is not as strong as in the walls, and the superficial layers are not as firmly attached (Nickel et al. 1981), (Monteiro-Riviere et al. 1993).

The most caudal part of the palmar/plantar portion of the digital organ is the bulbar segment. This is the posterior section of the ground surface aspect of the hoof. In this region, the horn is thinner and softer than the axial, abaxial and dorsal walls. It is because of this change that this area is more prone to cracks. The bulb forms a visible bulge, but provides a larger area to bear weight than in ruminants (Frandsen et al. 2009). The digital cushion, which gives the bulb some of its shape, is located in between the corium and the distal phalanx. This is the only segment of the digit to have subcutis present. It is a combination of connective tissue and adipose tissue and aids in shock absorption (Frandsen et al. 2009), (König et al. 2007).

## Epidermis

The epidermis of the hoof is made up of three of the usual five epidermal layers (Monteiro-Riviere et al. 1993). Hoof wall is continuously growing where the stratum basale and stratum spinosum are in contact with the corium at the coronary band. The third and fourth layers, the stratum granulosum and lucidum, are absent in the hoof wall. The keratinocytes produced at the coronary band (proliferative zone) continue to differentiate and keratinize into the external horn cells of the stratum corneum making up the tubular and intertubular horn of the hoof wall (Zimmerman et al. 2012), (Pollitt 2004). These cells are continuously added to the proximal hoof wall and make up the dorsal, axial and abaxial walls and the sole. The hard keratins of the wall of the hoof have mostly disulphide bonds, versus the sulfhydryl bonds of the periople, bulb and the white line. Disulphide bonds between the long fibrous molecules are necessary for the strength and insolubility of the keratins. The sulfhydryl groups in the periople, heel and white line make them weaker physically, but more elastic (Pollitt 2004).

## Dermal-epidermal junction

As previously mentioned, the connection between the epidermis and the dermis is extremely firm. The corium forms papillae that interdigitates with the epidermis. The perioplic and coronary corium have papillae that fit into the tubules of the epidermis (Pollitt 2004). These papillae are unique in each segment and horn tubules are produced over them. Keratinocytes form in between these epidermal tubules and form a matrix called the intertubular horn (Pollitt 2004). The papillae

are formed in the proximal horn, and as it continues distally, the number of papillae decreases. Periopic papillae are long and thin and lie vertical to the epidermis of the periople. Coronary papillae are short and narrow and usually overlap one another. The dermal component of the stratum internum does not form papillae, but instead laminae extend to form ridges vertical to the epidermis. As the matrix of coronary papillae merge into the parietal laminae the ridges change in to sheets. These laminar sheets connect the parietal epidermis to the parietal corium. In equine species, the stratum internum consists of approximately 600 primary epidermal laminae, which are continuous with the stratum medium. From these primary epidermal laminae, about one to two hundred secondary epidermal laminae project to interdigitate with the laminae of the corium. In ruminants and swine, neither the dermal nor the epidermal laminae have secondary laminae as seen in the horse (Pollitt 2004), (Monteiro-Riviere et al. 1993).

Like the axial, abaxial and dorsal hoof wall, the sole is also composed of keratinized epidermal layers. The sole corium has dermal papillae that fit in the sole horn. On the ground surface, at the distal end of each dermal laminae is the terminal sole papillae. These papillae join with the parietal epidermal laminae to create the junction between the sole and the hoof wall. In swine and ruminants this 'white line' is not very remarkable, since the hooves are generally unpigmented, but this soft and flexible white zone is distinct in horses (Monteiro-Riviere et al. 1993). This region lacks the disulfide bonds that constitute hard keratin, and due to the soft, elastic nature of this area, it can be prone to infection and degeneration. Caudally, the horn of the sole horn blends with the horn of the bulb/heel. Closer to the sole,



the bulb is approximately as thick and as firm. Caudally, the bulbs fuse and become continuous with the hairy skin.

### Comparative anatomy

Overall, the hooves of pigs are most similar to those of ruminants. Ruminants also have two weight bearing digits, three and four. The second and fifth digits, accessory digits, are less functional and do not contact the ground like in swine. Unlike swine, these rudimentary dewclaws do not have all three phalanges, and metacarpal/metatarsal bones but instead only have one or two phalanges and incomplete metacarpal/metatarsal bones. Small ruminants are often missing these bones all together and the dewclaws are just cutaneous structures (Nickel et al. 1981). It is thought that the basic structure of the hoof is very similar in ruminants and swine, except for the bulb of the ruminant hoof is larger. The equine hoof is unique in its weight bearing properties. Horses have six parts of the hoof, the periople, the coronet, the wall, the sole, the frog and the bulb. Unlike ruminants and swine that bear weight on the horny sole and bulb, horses use the frog and a small part of the sole to carry their weight.

### Current therapies

There are a few current recommendations for the correction of unequal weight bearing or hoof overgrowth, and one option is trimming. Not only can trimming overgrown hooves decrease the chances of lameness, but also it might improve sow productivity. While a relatively new concept in the swine industry, a

team of swine veterinarians across the United States has recently put together a sow claw trimming protocol. This protocol incorporates a chute designed to restrain the sow as well as provide easy access to the claws. The four main steps include trimming claw overgrowth, straightening the angle of the dorsal wall, creating a level sole and heel area and trimming the dew claws (Zinpro 2014).

Currently, little research has been done to investigate the anatomy of the porcine distal limb and additional research in this area could strengthen the trimming recommendations.

#### References

- Anil, Leena, Sukumarannair Anil, and John Deen. 2007. "Claw lesions predict lameness in breeding sows." *2007 Allen D. Leman Swine Conference*.
- Anil, Sukumarannair. S. and John Deen. 2007. "U.S. Year- End Summary" *Benchmark – PigCHAMP Year in Review 2*: 10-11.
- Anil, Sukumarannair S., Leena Anil, and John Deen. 2005. "Evaluation of patterns of removal and associations among culling because of lameness and sow productivity traits in swine breeding herds." *Journal of the American Veterinary Medical Association* 226: 956-961.
- Anil, Sukumarannair S., Leena Anil, and John Deen. 2009. "Effect of lameness on sow longevity." *Journal of the American Veterinary Medical Association* 235: 734-738.
- "Assessing Foot Health in Sows" last modified November 16, 2010. <http://nationalhogfarmer.com/genetics-reproduction/sow-gilt/assessing-foot-health-in-sows-1115>. National Hog Farmer, accessed February 10, 2014.

- Ciaco de Carvalho, Victor, Irenilza de Alencar Naas, Mario Mollo Neto and Silvia Regina Lucas de Souza. 2009. "Measurement of pig claw pressure distribution." *Biosystems Engineering* 103: 357-363.
- Dewey, Catherine E., Robert M. Friendship and Michael R. Wilson. 1993. "Clinical and postmortem examination of sows culled for lameness." *Canadian Veterinary Journal* 34: 555-556.
- "Feet First: Sow Lameness Prevention." *Zinpro Performance Minerals*. Zinpro Corporation, accessed 24 Feb. 2014. <http://www.zinpro.com/lameness/swine>
- Fitzgerald, Robert F., Kenneth J. Stalder, Locke A. Karriker, Lawrence J. Sadler, Howard T. Hill, Jeffrey Kaisand, and Anna K. Johnson. 2012. "The effect of hoof abnormalities on sow behavior and performance." *Livestock Science* 145: 230-238.
- Frandsen, Rowen D., W. Lee Wilke, and Anne Dee Falls. *Anatomy and Physiology of Farm Animals*. Ames: Wiley Blackwell, 2009.
- Gillespie, James R., and Frank B. Flanders. *Modern Livestock & Poultry Production*. Clifton Park: Cengage Learning, 2009.
- Hill, C., E. Raizman, T. Snider, S. Goyal, M. Torremorell and A.M. Perez. 2014. "Emergency of porcine epidemic diarrhea in North America. *Focus On* 9: 1-8.
- Honeyman, Mark S. and Colin Johnson. 2002. "Sow and Litter Performance of Individual Crate and Group Hoop Barn Gestation Housing Systems: A Progress Report." *Iowa State Research Farm Progress Reports*. [http://lib.dr.iastate.edu/farms\\_reports/1449](http://lib.dr.iastate.edu/farms_reports/1449)
- Knaur, Mark, Locke A. Karriker, Thomas J. Baas, Colin Johnson, and Kenneth J. Stalder. 2007. "Accuracy of sow culling classifications reported by lay personnel on commercial swine farms." *Journal of the American Veterinary Medical Association* 231: 433-436.

Knaur, Mark, Ken Stalder, Tom Baas, Colin Johnson and Locke Karriker. 2012. "Physical Conditions of Cull Sows Associated with On-Farm Production Records." *Open Journal of Veterinary Medicine* 2: 137-150.

König, Horst Erich., Hans-Georg Liebich, and H. Bragulla. "Common Integument," in *Veterinary Anatomy of Domestic Mammals: Textbook and Colour Atlas*. (Stuttgart: Schattauer, 2007), 585-635.

McBride, William D. and Nigel Key. "U.S. Hog Production From 1992 – 2009: Technology, Restructuring, and Productivity Growth." United States Department of Agriculture: Economic Research Service. October 2013. [www.ers.usda.gov/publications/eibeconomic-researchreport/err158](http://www.ers.usda.gov/publications/eibeconomic-researchreport/err158)

Monteiro-Riviere, Nancy A., Al W. Stinson, and H. Lois Calhoun. "Integument," in *Textbook of Veterinary Histology*, ed. H. Dieter Dellmann. (Philadelphia: Lea & Febiger, 1993), 285-312.

Nickel, Richard, August Schummer and Eugen Seiferle. *The Anatomy of Domestic Animals: The Circulatory System, the Skin and the Cutaneous Organs of the Domestic Mammals*. Berlin: Verlag Paul Parey, 1981.

Nickel, Richard, August Schummer and Eugen Seiferle. *The Anatomy of Domestic Animals: The Locomotor System of the Domestic Mammals*. Berlin: Verlag Paul Parey, 1986.

Nielsen, B., G. Su, M.S. Lund, and P. Madsen. 2013. "Selection for increased number of piglets at d 5 after farrowing has increased litter size and reduced piglet mortality." *Journal of Animal Science* 91:2575-2582.

"Overview of the US Hog Industry." United States Department of Agriculture: National Agricultural Statistics Service, released October 30, 2009. [www.nass.usda.gov](http://www.nass.usda.gov)

Pollitt, Christopher C. 2004. "Anatomy and Physiology of the Inner Hoof Wall." *Clinical Techniques in Equine Practice* 7: 3-21.

“Porcine Epidemic Diarrhea,” America Association of Swine Veterinarians: Quick Facts, released November 18, 2013.

“Quarterly Hogs & Pigs,” United States Department of Agriculture: National Agricultural Statistics Service, released September 26, 2014. ISSN: 1949-1921.

Schenk, Erin L., Jeremy N. Marchant-Forde and Donald C. Lay Jr. 2010. “USDA Sow Lameness and Longevity.” *USDA Sow Welfare Fact Sheet: Livestock Behavior Research Unit*.

Serenius, T. and K. J. Stalder. 2006. “Selection for sow longevity.” *Journal of Animal Science* 84 (E.Suppl.): E166-E171.

Sisson, Septimus, James Daniels Grossman, and Robert Getty. "Porcine Osteology," in *Sisson and Grossman's The Anatomy of the Domestic Animals*. 1216-1252. Philadelphia: Saunders, 1975.

Sun, Gang, Robert F. Fitzgerald, Kenneth J. Stalder, Locke A. Karriker and Anna K. Johnson. 2011. “Development of an Embedded Microcomputer-based Force Plate System for Measuring Sow Weight Distribution and Detection of Lameness.” *Agricultural and Biosystems Engineering Publications* 27:475-482.

“Swine 2006 - Part I: Reference of Swine Health and Management Practices in the United States.” United States Department of Agriculture, Animal and Plant Health Inspection Service, released October 2007. #N475.1007

“Swine 2006 - Part III: Reference of Swine Health, Productivity, and General Management in the United States.” United States Department of Agriculture, Animal and Plant Health Inspection Service, 2008. #N478.0308

“U.S. Hog Breeding Herd Structure.” United States Department of Agriculture: National Agricultural Statistics Service, released September 22, 2006. [www.nass.usda.gov](http://www.nass.usda.gov).

Zimmerman, Jeffrey J., Locke A. Kariiker and Alejandro Ramirez, Kent J. Schwartz and Gregory Stevenson. *Diseases of Swine*. Tenth ed. Ames: Blackwell, 2012.

CHAPTER 3. GROSS ANATOMICAL MEASUREMENTS AND MICROSCOPIC  
QUANTIFICATION OF EPIDERMAL LAMINAR DENSITY OF THE PORCINE HOOF  
CAPSULE

A paper to be submitted to the *Journal of Animal Science*

Meghan E. Fick, Wolfgang Weber, Locke A. Karriker, Kenneth J. Stalder, Eric W. Rowe

**Abstract**

Differences in hoof wall measurements between the forelimbs and hind limbs and the medial and lateral digits have been underreported in swine. Most of the information on the anatomy of the porcine hoof capsule has been extrapolated from studies on ruminants or horses. Lesions of the hoof capsule in sows are a problem commonly encountered in the swine industry. This leads to detrimental effects on animal welfare and causes economic losses for producers. Little research has been done on the correlation between the sow's inherent anatomy and the frequency or location of the lesions.

The aims of this study were to compare measurements of the medial and lateral hooves of the forelimbs and hind limbs; and to quantify the density of epidermal laminae in sows. The hoof measurements were obtained from forty thoracic limbs and forty pelvic limbs of clinically sound sows. The epidermal laminae were counted on 143 limbs, sixty-nine thoracic limbs and seventy-four pelvic limbs.

The lateral digits of the hind limbs were found to be longer both on the dorsal and volar surfaces than the medial digits. These same measurements were

not significantly different in the forelimbs, but both digits on the forelimbs had wider soles than those of the hind limbs. The thickness (depth) of the abaxial wall when compared to the dorsal wall was significantly different ( $p < 0.0001$ ). The laminar zones at the axial and abaxial extremities of the wall were significantly less dense ( $p < 0.0001$ ) than the zones located at the dorsal aspect of the toe. These results suggest that previously reported abaxial wall lesions are more likely to cause clinical lameness due to the thin nature of the hoof capsule in this location.

### **Introduction**

Lameness in swine is a frequently encountered cause for compromised animal welfare and reduced efficiency. Retaining healthy sows and gilts is a vital component in avoiding unnecessary losses and incurring unwanted costs. Involuntary culling, or removal of animals from the herd due to low production caused by poor health, low output or incurable disease before the end of their productive lifespan, is generally less profitable than voluntary culling because the producer is not prepared for it (Dagorn and Aumaitre 1979). Lamé sows are frequently unable to attain their ideal breeding efficiency and are often culled before they reach their peak production (D'Allaire et al. 1987).

In breeding sows, the most common causes of lameness seen are hoof lesions, trauma, osteochondrosis, fractures, skin lesions and arthritis (Heinonen et al. 2013). The cause of lameness may not be apparently evident since physical examinations are difficult to perform, and often times there is more than one lesion causing the lameness. The most common hoof lesions seen are overgrown hooves,



torn dewclaws, hoof cracks, white line cracks, cracks at the heel-sole junction or sole ulcers (Nalon et al. 2013, Dewey et al. 1993).

An important function of the porcine hoof is protection of the terminal limb structures. When the integrity of the hoof capsule has been compromised and the sensitive dermis has been exposed, the sow becomes lame. The basic anatomy of the porcine hoof has been described in various anatomy textbooks, but detailed investigation of the depth and measurements of various aspects of the hoof wall have yet to be determined. Most of the assumed information has been extrapolated from studies on equine and bovine hooves. A better understanding of the depth at different locations of the porcine hoof capsule, as well as determining the density and laminar structure in sows, may provide an anatomical correlation to previously documented hoof lesions and aid producers and swine veterinarians in formulating preventative measures or treatment plans for lame sows. The purpose of this study was to create a basic reference for normal porcine hoof measurements as well as quantify the density of epidermal laminae.

## **Materials and Methods**

### *Measurement of Hoof Wall Dimensions*

For this study, forty forelimbs and forty hind limbs were obtained from mixed breed sows participating in an Agriculture and Food Research Initiative lameness trial. The sows were not clinically lame at the time of euthanasia and the distal limb was disarticulated in the carpal or metacarpal region. Most of the limbs were labeled, right vs. left and front vs. rear at the time of necropsy. If they were not differentiated right from left, the carpal or tarsal bones were used to identify the

limb. In cases where the disarticulation was distal to the carpus or tarsus, the tendons of the long or common digital extensor and lateral digital extensor muscles were used. Feet that were grossly abnormal were discarded from the study. The weight, age and parity of these sows are unknown.

The limbs were frozen until they were ready for use. They were thawed either at room temperature for approximately 12 hours or in a cooler for 24-36 hours prior to obtaining measurements. Measurements were taken in a manner similar to a study on post-mortem cows (Nuss and Paulus, 2006). All holes were drilled with a standard electric drill and all depth and length measurements were taken with a ProGrade® electronic digital caliper.

Three approximately 6 mm holes (1/4" drill bit) were drilled into each digit, measuring the dorsal wall depth, the abaxial wall depth and the sole depth. The dorsal wall depth was measured at the most proximal aspect, while the abaxial wall depth was measured at the most palmar/plantar aspect of their respective holes. The sole was measured in four sites: cranial, caudal, axial and abaxial (Fig. 1).

The dorsal wall length was measured from the most proximal aspect of the perioplic segment to the most distal aspect of the toe. The same location on the distal aspect of the toe to the caudal most aspect of the bulb was used to determine the ground surface. The palmar/plantar most aspect of the ground surface was used as the initial measurement for the abaxial wall height. The calipers were placed approximately perpendicularly to the ground surface and measured from there to the haired skin (Fig. 2).

Sole width was measured at the caudal most aspect of the axial sole in the interdigital space across to the abaxial surface at an approximate 90° angle to the ground surface measurement. The sole + wall length was measured in the same manner as the ground surface, from the center of the distal toe, but only extends the length of the sole, where hard and soft horn meet (Fig. 3). This measurement includes the sole, the white line and the wall. For each sample, three measurements were taken at each location and the average of the three was used for statistical analysis.

#### *Quantification of Epidermal Laminae*

For the second part of the study, 69 forelimbs and 74 rear limbs from sows were obtained from a slaughterhouse. The limbs were disarticulated at the distal metacarpus or the proximal phalanges. These limbs were not differentiated right from left, and both digits from each limb were regarded in the same manner. The limbs were initially frozen, keeping the forelimbs separate from the rear limbs, and then thawed for approximately 12 hours at room temperature until the digits could be manipulated separately.

Commercially obtained cable ties were used to secure them to pieces of plywood in a weight bearing position. To accomplish this, the dorsal aspect of the distal limb was laid on a rectangular, 15-20 cm wide and 30-40 cm long, piece of plywood and 1-2 cable ties were used to secure it. A second piece of plywood, an approximate 10 x 10 cm, was placed on the ground surface of the hoof and secured to the first piece of plywood with a screw in the interdigital space. After the feet were once again frozen, the cable ties and wood were removed (Fig. 4 & Fig. 5).

The feet were sliced with a band saw at an approximate 30-35° angle from the ground surface. Each slice was approximately 5 mm in thickness. The slices were labeled 1-4, with 1 being the most distal slice and 4 being the most proximal slice (Fig. 6). The distal and proximal aspect of each slice was inspected to determine the best sample to visualize the epidermal laminae.

The laminar junction was stained with a 5% methylene blue stain solution and immediately placed in 70% alcohol for 5 minutes, rinsed with distilled water, and placed back in the 70% alcohol for another 5 minutes. The slice was blotted dry with a paper towel and then allowed to air dry.

Under a dissecting microscope, the density of epidermal laminae was analyzed in a manner similar to that reported by Barreto-Vianno et al. (2013). The most dorsal aspect of the slice, or the location where the epidermal laminae turned away from each other, was selected as Point #1. From this point, the laminar junction was divided into zones of 25 laminae each. The zones started at the dorsal aspect of the toe, and moved axially and abaxially with A, C, E and J on the axial surface and B, D, F, G, H and I on the abaxial surface (Fig. 7). Pins were used as markers to differentiate between each zone. The same ProGrade® electronic digital caliper was used to make all of the measurements from the shaft of adjacent pins. This 'zone width' was used to determine epidermal density, with smaller widths being more dense and larger widths being less dense. The frequency of branching in each zone was also examined. Each laminae was counted individually, and branching laminae were labeled as such. Laminae could have proximal branching, closer to the dermis, or distal branching, closer to the epidermis. For each sample,

three measurements were taken at each location and the average of the three was used.

### *Statistical Analysis*

Variances in hoof wall measurements and density of epidermal laminae of the forelimbs and rear limbs were quantified and analyzed with JMP Pro 11 using a one-way analysis of variance (ANOVA) followed by Student's t test with the significance level set at  $P < 0.05$ .

## **Results**

### *Hoof Wall Measurements*

#### Dorsal Wall Length

The dorsal wall length of right rear digit IV was significantly longer than that of both left and right rear digit III ( $p < 0.0001$ ). Left rear digit III is significantly longer than left front digit III ( $p = 0.0028$ ) and right front digit III ( $p = 0.0028$ ) and right rear digit III is significantly longer than left front digit III ( $p = 0.0145$ ) and right front digit III ( $p = 0.0146$ ). Digit IV of the left rear limb had a significantly longer dorsal wall than that of left rear digit III ( $p = 0.0002$ ) and right rear digit III ( $p = 0.0013$ ). The length of digit IV on both rear limbs was significantly longer than all four digits on the forelimbs ( $p < 0.0001$ ). As seen in Table 1, all four digits on the forelimbs are shorter than the lateral digits of the hind limbs. These rear lateral digits are significantly longer than the other six digits.

#### Abaxial Wall Height

Left front digit III showed significant difference in the abaxial wall height of left rear digit IV ( $p = 0.0019$ ) when compared to left rear digit III ( $p = 0.0096$ ). The

abaxial wall of right front digit III is taller than right rear digit III ( $p=0.0045$ ). Right front digit IV is significantly taller than left rear digit III ( $p=0.0009$ ), right front digit III ( $p=0.005$ ), and left rear digit IV ( $p=0.0001$ ). Right rear digit III has a significantly shorter height of the abaxial wall than right front digit IV, left front digit III and IV, and right rear digit IV ( $p < 0.0001$ ). Table 1 shows that there is no real significant correlation between any digits, left and right, or forelimb and hind limb or lateral digit and medial digit with this measurement.

#### Sole Width

All four digits on the forelimbs have a significantly wider sole than digit III on both the left and right rear limb ( $p<0.0001$ ). Left and right rear digits IV are significantly wider than left and right rear digits III ( $p<0.0001$ ). Left front digit III is significantly wider than left rear digit IV ( $p=0.0042$ ) and right rear digit IV ( $p=0.0076$ ). Left front digit IV is significantly wider than left rear digit IV ( $p=0.0003$ ) and right rear digit IV ( $p=0.0007$ ). Right front digit III is significantly wider than left rear digit IV ( $p=0.0197$ ) and right rear digit IV ( $p=0.0324$ ). Right front digit IV is significantly wider than left rear digit IV ( $p=0.0009$ ) and right rear digit IV ( $p=0.0017$ ). The forelimbs have wider soles than all four digits on the hind limbs. The medial digit on the rear limbs had the narrowest soles of all eight digits. This information can be seen in Table 1.

#### Sole + Wall Length

Left front digit III's sole + wall length measures significantly longer than left rear digit III ( $p=0.0016$ ) and right rear digit III ( $p=0.0485$ ). This measurement on left front digit IV is significantly longer than left rear digit III ( $p<0.0001$ ) and right

rear digit III ( $p=0.0023$ ). The length of the sole + the wall of right rear digit IV is significantly longer than all four digits on the forelimbs and digit III on the left rear and right rear limbs ( $p<0.0001$ ). This measurement of the left rear digit IV is significantly longer than left front digit III, right front digit III and digit IV, right rear digit III and left rear digit III ( $p<0.0001$ ). Right front digit III and right front digit IV are both significantly longer than left rear digit III ( $p=0.0099$  and  $p=0.0009$ ). Right front digit IV is longer than right rear digit III ( $p=0.0348$ ) and left rear digit IV is longer than left front digit IV ( $p=0.0014$ ). Table 1 shows that the lateral digits on the hind limbs had the longest sole + wall length of all eight digits, while digit III was the shortest.

#### Ground Surface

The ground surface of left front digit III is significantly longer than right rear digit III ( $p=0.0453$ ). Left front digit IV is longer than left front digit III ( $p=0.0378$ ), left rear digit III ( $p=0.0002$ ), and right rear digit III ( $p<0.0001$ ). Right front digit III is longer than left rear digit III ( $p=0.0178$ ) and right rear digit III ( $p=0.0077$ ). Right front digit IV is significantly longer than left front digit III ( $p=0.0385$ ), left rear digit III ( $p=0.0002$ ), and right rear digit III ( $p<0.0001$ ). Left rear digit IV is significantly longer than all IV medial digits (front and rear digits III,  $p<0.0001$ ). The same digit is also significantly longer than left front digit IV ( $p=0.0108$ ) and right front digit IV ( $p=0.0106$ ). Right rear digit IV is significantly longer than the left front and right front digit IV ( $p=0.0002$ ) as well as all four medial digits ( $p<0.0001$ ). The lateral digits of the hind limbs were the longest, while the medial digits were the shortest as seen in Table 1. The digits of the forelimbs were found in between.

### Dorsal Wall Depth

Table 2 shows that the dorsal wall of left rear digit IV is significantly thicker than left front digit III ( $p=0.0062$ ), left front digit IV ( $p=0.0028$ ), right front digit III ( $p=0.0005$ ), right front digit IV ( $p=0.0444$ ), left rear digit III ( $p=0.213$ ), and right rear digit III ( $p=0.0140$ ). The dorsal wall of right rear digit IV is thicker than left front digit III ( $p=0.0088$ ), left front digit IV ( $p=0.0041$ ), right front digit III ( $p=0.0008$ ), left rear digit III ( $p=0.0287$ ) and right rear digit III ( $p=0.0191$ ). The left and right rear digit IV had a deeper dorsal wall than any digit on the forelimb. There was no significant difference when comparing any of the four digits of the forelimb.

### Abaxial Wall Depth

Left rear digit III was significantly thinner when compared to left front digit III ( $p=0.0309$ ), right front digit IV ( $p=0.0328$ ), and right rear digit IV ( $p=0.0490$ ). When comparing the lateral to medial digits and forelimb to hind limb digits, there was no consistent significant differences, as seen in Table 2.

### Sole Depth

Left rear digit IV's cranial sole depth was significantly different than left front digit III ( $p=0.0087$ ) and right front digit III ( $p=0.0084$ ). Right rear digit IV is significantly thicker than left front digit III ( $p=0.0014$ ), left front digit IV ( $p=0.0489$ ), right front digit III ( $p=0.0013$ ), left rear digit III ( $p=0.0162$ ), and right rear digit III ( $p=0.0128$ ).

The caudal sole depth of right front digit IV is significantly thicker than right front digit III ( $p=0.0479$ ). Left rear digit IV was significantly thicker than left front



digit III and right front digit III ( $p < 0.0001$ ), as well as left front digit IV ( $p = 0.0034$ ), right front digit IV ( $p = 0.0417$ ), left rear digit III ( $p = 0.0079$ ), and right rear digit III ( $p = 0.0023$ ). Right rear digit IV is significantly thicker than right front digit IV ( $p = 0.0018$ ), left rear digit III ( $p = 0.0002$ ) and left front digit III, left front digit IV, right front digit III and right rear digit III ( $p < 0.0001$ ).

The sole axial depth of left rear digit IV is significantly thicker than left front digit III ( $p = 0.0083$ ) and left rear digit III ( $p = 0.0392$ ). The right rear digit IV is significantly thicker than left front digit III ( $p = 0.0004$ ), left front digit IV ( $p = 0.0369$ ), right front digit III ( $p = 0.0080$ ), right front digit IV ( $p = 0.0309$ ), left rear digit III ( $p = 0.0020$ ) and right rear digit III ( $p = 0.0075$ ).

The sole abaxial depth of right front digit IV is significantly thicker than right front digit III ( $p = 0.0163$ ). Left rear digit IV is significantly thicker in the abaxial portion of the sole of left front digit III ( $p = 0.0018$ ), left front digit IV ( $p = 0.0123$ ), right front digit III ( $p = 0.0002$ ), left rear digit III ( $p = 0.0217$ ), and right rear digit III ( $p = 0.0063$ ). Right rear digit IV is thicker at this location than right front digit IV ( $p = 0.0083$ ), left rear digit III ( $p = 0.0003$ ) as well as left front digit III, left front digit IV, right front digit III and right rear digit III ( $p < 0.0001$ ). Overall, the lateral digits of the hind limb, had the deepest sole measurements, with the medial digits of the forelimb being the thinnest. This information can be seen in Table 2.

#### Dorsal Wall Depth vs. Abaxial Wall Depth

The dorsal wall depth of left rear digit IV and right rear digit IV was significantly thicker than the abaxial wall depth on all eight digits ( $p < 0.0001$ ). The left and right rear medial digit is significantly thicker at the dorsal wall than the

abaxial wall on left front digit IV, right front digit III, left rear digit III, left rear digit IV and right rear digit III ( $p < 0.0001$ ). The remaining three digits are also significantly thinner (left front digit III, right front digit IV, right rear digit IV) than the rear medial digits. All differences in thickness between digits on the dorsal wall, as seen in Table 2, when compared to the abaxial wall are significant.

#### Dorsal Wall Depth vs. Sole Depth

The dorsal wall of right rear digit IV is significantly thicker than the cranial sole of all eight digits ( $p < 0.0001$ ). The dorsal wall of left rear digit IV is significantly thicker than the cranial sole of all four digits on the forelimbs and the medial digits on the hind limbs ( $p < 0.0001$ ) as well as the lateral digits of the right rear limb ( $p = 0.0002$ ) and the left rear limb ( $p = 0.0003$ ). The lateral digit of the right forelimb has a thicker dorsal wall than cranial sole measurement on right forelimb digit III, left forelimb digit III and IV, left and right rear limbs digit III ( $p < 0.0001$ ), and right forelimb digit IV ( $p = 0.0002$ ). The lateral digit of the left forelimb is significantly thicker on the dorsal wall than cranial sole in digits III and IV of the left forelimb, and digit III of the right forelimb ( $p < 0.0001$ ). It's also thicker than the cranial sole in the medial digit of both right ( $p = 0.0003$ ) and left ( $p = 0.0004$ ) forelimb and lateral digit of the right forelimb ( $p = 0.0008$ ).

The caudal sole depth of all eight digits is significantly thinner than the dorsal wall depth on right rear and left rear digit IV. ( $p < 0.0001$ ). The dorsal wall of right front digit IV is significantly thicker than the caudal sole depth on all four digits of the forelimbs ( $p < 0.0001$ ). Left front digit IV has a significantly thicker dorsal wall

than both digits on the left forelimb and right front digit III ( $p < 0.0001$ ), as well as the right front digit IV ( $p = 0.0004$ ).

The axial aspect of the sole of all eight digits was significantly thinner than the dorsal wall of right rear digit IV ( $p < 0.0001$ ). The left rear digit IV was significantly thinner in the abaxial wall region than the dorsal wall region of all four digits of the forelimb and both medial digits of the hind limb ( $p < 0.0001$ ).

The abaxial sole depth of all eight digits was significantly thinner than the dorsal wall depth of the right rear digit IV ( $p < 0.0001$ ). The lateral digit of the left rear limb and right forelimb had a thicker dorsal wall than abaxial sole on all four forelimbs and the medial digit of both hind limbs ( $p < 0.0001$ ). The lateral digit of the left forelimb had a thicker dorsal wall than abaxial sole of the medial and lateral digit of the left forelimb as well as the medial digit of the right forelimb ( $p < 0.0001$ ). Overall, when comparing the dorsal wall to all four measurements of the sole, the dorsal wall is consistently thicker on any digit than that of the sole at the cranial, caudal, axial or abaxial aspect. This information is displayed in Table 2.

#### Sole Depth vs. Abaxial Wall Depth

As seen in Table 2, the left front digit III and IV, right front digit III and IV, left rear digit III and IV, and right rear digit III and IV are significantly thicker in the region of the cranial, caudal, axial and abaxial sole than the abaxial wall ( $p < 0.0001$ ).

#### *Quantification of Epidermal Laminae*

#### Thoracic Limb Zone Width

Zone A was significantly narrower than Zones C, D, E, F, G, H, I and J ( $p < 0.0001$ ). Zone B was significantly narrower than Zones C, D, E, F, G, H, I, and J

( $p < 0.0001$ ). Zone C was narrower than Zones E, F, G, H, I, and J ( $p < 0.0001$ ). Zone D was significantly narrower than Zones E, F, G, H, I ( $p < 0.0001$ ) and Zone J ( $p = 0.0002$ ). Zone E was significantly narrower than Zones G, I and H ( $p < 0.0001$ ). Zone F was narrower than Zones G, H and I ( $p < 0.0001$ ). In the thoracic limb, epidermal laminae are most dense in the dorsal region and less dense in the abaxial wall and axial portion of the digit in the interdigital space.

#### Pelvic Limb Zone Width

Zone A was significantly narrower than Zones C, D, E, F, G and H ( $p < 0.0001$ ). Zone B was significantly narrower C, D, E, F, G and H ( $p < 0.0001$ ). Zone C was significantly narrower Zone E, F, G and H ( $p < 0.0001$ ) and was wider than Zone A and B ( $p < 0.0001$ ). Zone D was narrower than Zones F, G, and H ( $p < 0.0001$ ) as well as Zone E ( $p = 0.0004$ ). Zone E was more narrow than Zones F, G, and H ( $p < 0.0001$ ). Zone F is narrower than Zone G ( $p = 0.001$ ) and Zone H ( $p = 0.0047$ ). Like the thoracic limb, the pelvic limb epidermal laminae are most dense at the dorsal region of the toe and lease dense at the far plantar region.

#### Thoracic Limb vs. Pelvic Limb Zone Width

Pelvic limb zone A and B are significantly the narrowest zones, being narrower than Zones C, D, E, F, G and H on both the pelvic and thoracic limbs and Zones I and J on the pelvic limb ( $p < 0.0001$ ). Thoracic limb Zone A and B are significantly more narrow than Zones D, E, F, and H on the thoracic and pelvic limbs and Zones C, I and J on just the pelvic limbs ( $p < 0.0001$ ). Zone E of the pelvic limb is significantly wider than Zones A, B, C and D on both the pelvic and thoracic limbs ( $p < 0.0001$ ) while Zone E of the thoracic limb is wider than Zones A and B on the

thoracic limbs ( $p < 0.0001$ ). When the thoracic limb and pelvic limb are compared to one another, the zones maintain the same pattern of highest density at the dorsal part of the toe, and lowest density at the abaxial wall. The pelvic limb is significantly less dense in the abaxial wall region than thoracic limb.

### Thoracic Limb Branching

The branching frequency in Zone A and Zone B are significantly different than that of Zones E, G and H ( $p < 0.0001$ ) with Zones A and B having less branching laminae. Zones C and D also have less branching than Zones G or H ( $p = 0.0011$ ). Zone F has less branching than Zones E and G ( $p = 0.0003$ ). There was more branching laminae per zone at the palmar aspect of the hoof versus the toe.

### Pelvic Limb Branching

Zone A has significantly less laminar branching than Zones C ( $p = 0.0453$ ), D ( $p = 0.0001$ ), E ( $p = 0.0018$ ), F ( $p < 0.0001$ ), and G ( $p = 0.0001$ ). Zone B has less branching in Zones D ( $p = 0.0005$ ), E ( $p = 0.0051$ ), G ( $p = 0.0003$ ) and H ( $0.0004$ ). The zones at the dorsal aspect of the hoof had significantly less laminar branching than the zones at the plantar abaxial wall.

### **Discussion**

Results of this study suggest that there is a correlation between the gross morphology of the porcine hoof capsule and the location of hoof lesions and subsequent lameness. Research has been ongoing for decades as to the prevalence of foot lesions in sows. This research has been linked with genetic causes, environmental causes, nutrition, infection, and leg conformation (Zimmerman et al.

2012). The inherent anatomy of the porcine hoof capsule can now be related to lameness in sows.

The main objective of this study was to further investigate the anatomy of the porcine hoof wall and draw conclusions about predispositions to foot lesions based on this inherent anatomy. A second goal was to establish known values for various measurements (lengths and depths) of swine hooves in order to encourage hoof trimming in eligible lame sows rather than culling. Some of the most significant findings in this study reaffirmed research that has been done previously, such as the size disparity of the lateral and medial digits on the hind limb and the equal ground surface of the forelimbs ( Zimmerman et al. 2012). Previously unreported data showed that the thinnest portion of the hoof capsule was located at the abaxial wall. This corresponded with the least dense region of epidermal laminae.

Isolating the differences in thickness of the hoof capsule can point to areas that may be predisposed to cause lameness if foot lesions occur there. The hard epidermal hoof wall lies just over the supportive tissue layer, the corium. The corium contains blood vessels and nerves, making it sensitive to pain once exposed to the external environment. The corium is also essential for keratin formation, meaning that if this area is damaged or does not receive proper nutrients, the hoof will likely be of lesser quality and will be more susceptible to damage from the environment (Zimmerman et al. 2012). Hoof wall or sole cracks that are deep enough to expose the corium are more likely to result in lameness from pain.

As previously stated, this study is in agreement with previously reported data concluding that the lateral digits of the hind limbs were longer, both dorsally

and on the ground surface, than both the medial digits of the hind limb and the digits of the forelimb. The length of the dorsal wall, ground surface and sole width of the forelimbs was more comparable between lateral and medial digits than the greater disparity in size seen in the hind limbs. It has also been reported that hoof wall lesions are more frequently seen on the lateral hooves of the hind limb than on the medial hooves. It has been proven that the lateral digits of the hind limbs carry more weight than the medial digits, and therefore possibly more prone to developing lesions (Sun et al. 2011). Once these lesions occur, the associated pain can cause the sow to bear more weight on the other limb, leading to obvious lameness and possible injury to the other limb.

Areas of the hoof where hard horn meets soft horn are also prone to injury (where wall meets sole). A majority of the weight is born by the heel, one of the most frequent places to see cracks and erosions. One of the subsequent highest weight bearing regions is where the heel meets the abaxial hoof wall of the lateral digit (Zimmerman et al. 2012), (Anil et al. 2007), (Konig et al. 2007). Our data shows that this area is the thinnest region of the hoof capsule when compared to the sole and the dorsal wall. Cracks in the abaxial wall will have to be less severe in order to reach the corium, the sensitive layer of the hoof, and in turn for the sow to show signs of lameness. One study showed that there was a significant difference in severity of lesions on the abaxial wall as well as the white line in lame sows and sound sows (Anil, L. et al. 2007). This region was also found to have the least dense epidermal laminae when compared to the dorsal toe region. The paucity of laminae means there is less epidermal/dermal interaction, perhaps making this region more

susceptible to white line disease. The separation of the corium and epidermis commonly occurs on the abaxial border, frequently at the heel-sole junction (Konig et al. 2007). Due to the low density of laminae in this area and the thin abaxial wall, it is easier for minor damage to affect the sensitive corium and due to the location of the lesion, may lead to infections as well.

It has been long speculated that the association between hoof wall lesions and lameness was pain-mediated. Oftentimes, lameness is not overt in sows, and subtle signs often go untreated or are addressed too late, resulting in culling of the sow. With this new information, it would be reasonable to propose a pre-assessment for farm workers or producers in order to catch signs of lameness before they impact the sows. Since the weakest part of the hoof capsule was found to be the abaxial wall of the lateral digit of the hind limb, this one location would be simple to evaluate in routine inspections of the sows.

It is hoped that this manuscript will serve as a reference point to help guide hoof trimming techniques that will lead to better welfare management and decreased cull rates for lameness in breeding sows.

## References

- Anil, Leena, Sukumarannair Anil, and John Deen. 2007. "Claw lesions predict lameness in breeding sows." *2007 Allen D. Leman Swine Conference*.
- Anil, Sukumarannair S., Leena Anil, and John Deen. 2005. "Evaluation of patterns of removal and associations among culling because of lameness and sow productivity traits in swine breeding herds." *Journal of the American Association of Veterinary Medicine* 226: 956-961.



- Anil, Sukumarannair S., Leena Anil, and John Deen. 2007. "Association of parity, body condition and lactation feed intake with claw integrity in sows." *Allen D. Leman Swine Conference*. University of Minnesota, College of Veterinary Medicine Extension Service Swine Center.
- Barreto-Vianna, Andre R. C., Luana S. Oliveira, Andre S. Leonardo, Marcelo I. Santana, Roberta F. Godoy, and Eduardo M.M. de Lima. 2013. "Density of primary and secondary epidermal laminae of equine hoof." *Pesq. Vet. Bras.* 33: 543-548.
- Ciaco de Carvalho, Victor, Irenilza de Alencar Naas, Mario Mollo Neto and Silvia Regina Lucas de Souza. 2009. "Measurement of pig claw pressure distribution." *Biosystems Engineering* 103: 357-363.
- D'Allaire, S. T.E. Stein and A.D. Leman. 1987. "Culling Patterns in Selected Minnesota Swine Breeding Herds." *Canadian Journal of Veterinary Research* 51: 506-512.
- Dagorn, J. and A. Aumaitre. 1979. "Sow Culling: Reasons for and Effect on Productivity." *Livestock Production Science* 6: 167-177.
- Dewey, Catherine E., Robert M. Friendship, and Michael R. Wilson. 1993. "Clinical and postmortem examination of sows culled for lameness." *Canadian Veterinary Journal* 34: 555-556.
- Fitzgerald, Robert F., Kenneth J. Stalder, Locke A. Karriker, Lawrence J. Sadler, Howard T. Hill, Jeffrey Kaisand and Anna K. Johnson. 2012. "The effect of hoof abnormalities on sow behavior and performance." *Livestock Science* 145: 230-238.
- Heinonen, Mari, Olli Peltoniemi, and Anna Valros. 2013. "Impact of lameness and claw lesions in sows on welfare, health and production." *Livestock Science* 156: 2-9.
- König, Horst Erich., Hans-Georg Liebich, and H. Bragulla. "Common Integument," in *Veterinary Anatomy of Domestic Mammals: Textbook and Colour Atlas*. (Stuttgart: Schattauer, 2007), 585-635.
- Nalon, E., S. Conte, D. Maes, F.A.M. Tuytens, and N. Devillers. 2013. "Assessment of lameness and claw lesions in sows." *Livestock Science* 156: 10-23.

Nuss, K. and N. Paulus. 2006. "Measurements of claw dimensions in cows before and after functional trimming: A post-mortem study." *The Veterinary Journal* 172: 284-292.

Zimmerman, Jeffrey J., Locke A. Karriker, Alejandro Ramierez, Kent J. Schwartz and Gregory W. Stevenson, eds. 2012. *Diseases of Swine*. Ames: Wiley-Blackwell.

Figures & Tables

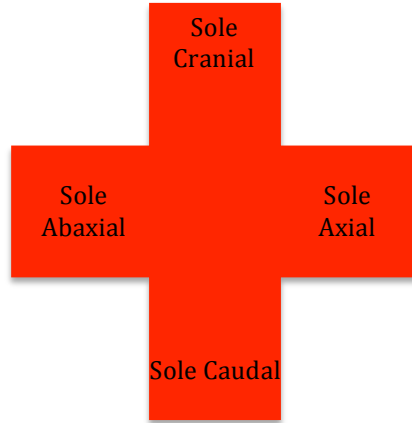


Figure 1: Location of sole depth measurements

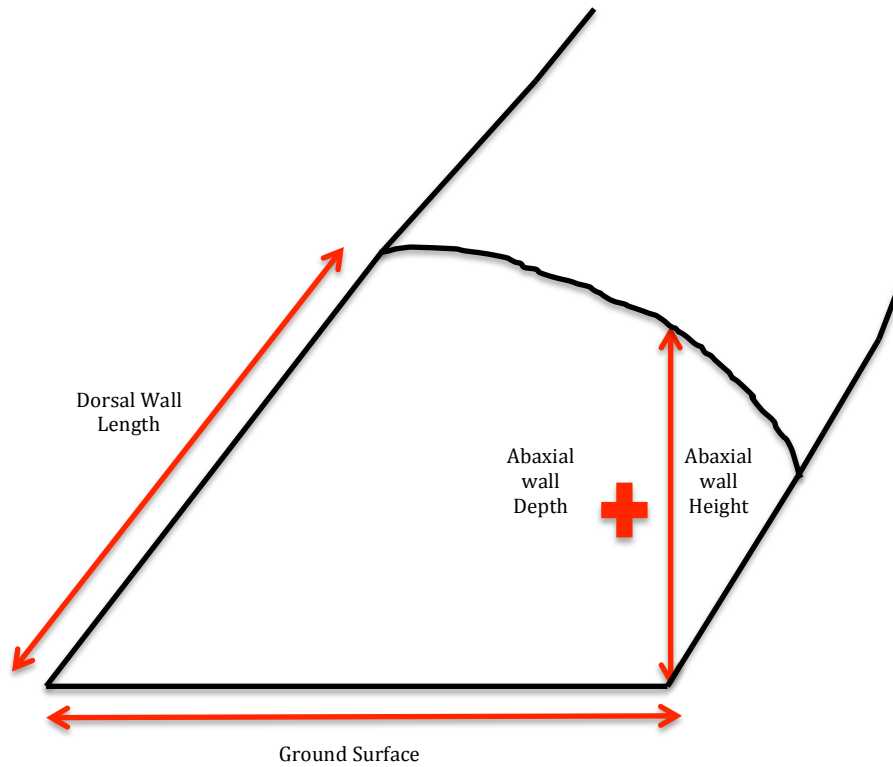


Figure 2: Schematization of hoof wall measurements as seen from the lateral aspect of the digit

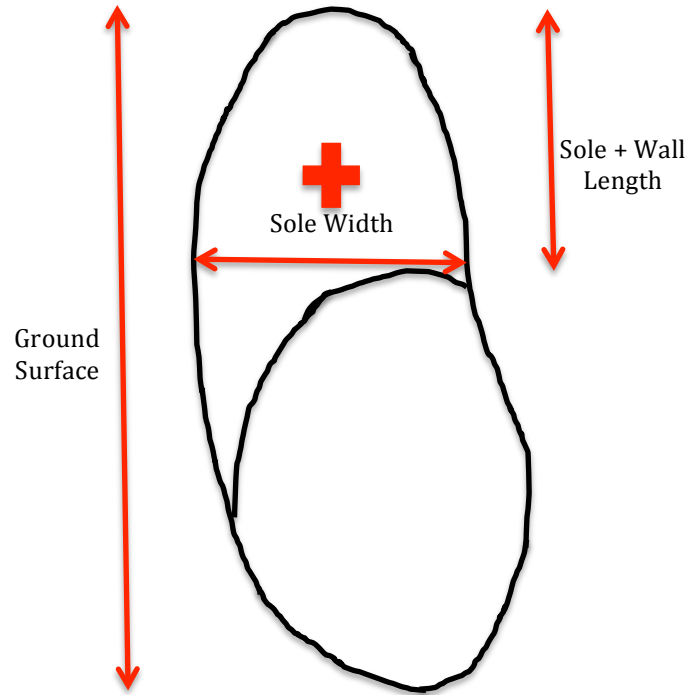


Figure 3: Schematization of hoof wall measurements as seen from the ground surface (volar) aspect of the digit

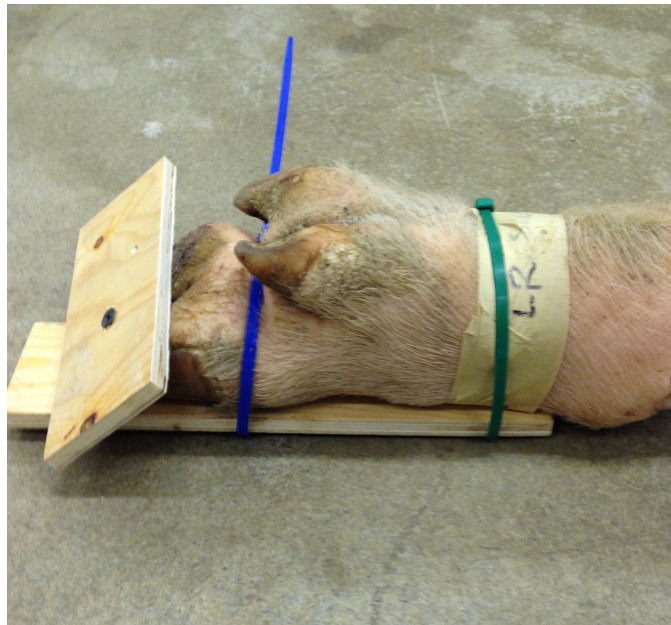


Figure 4: Example of use of plywood and cable ties to manipulate the distal limb into an assumed weight bearing position as seen from the plantar-lateral aspect

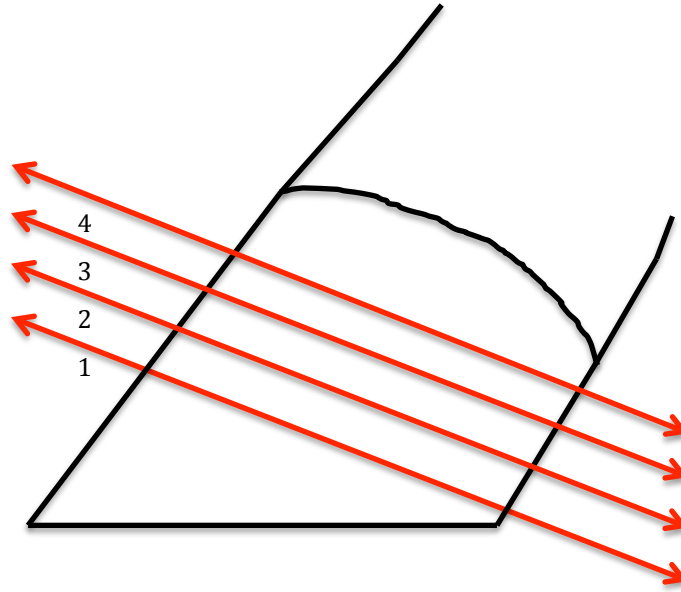


Figure 5: Schematization of hoof slices used to quantify epidermal laminae

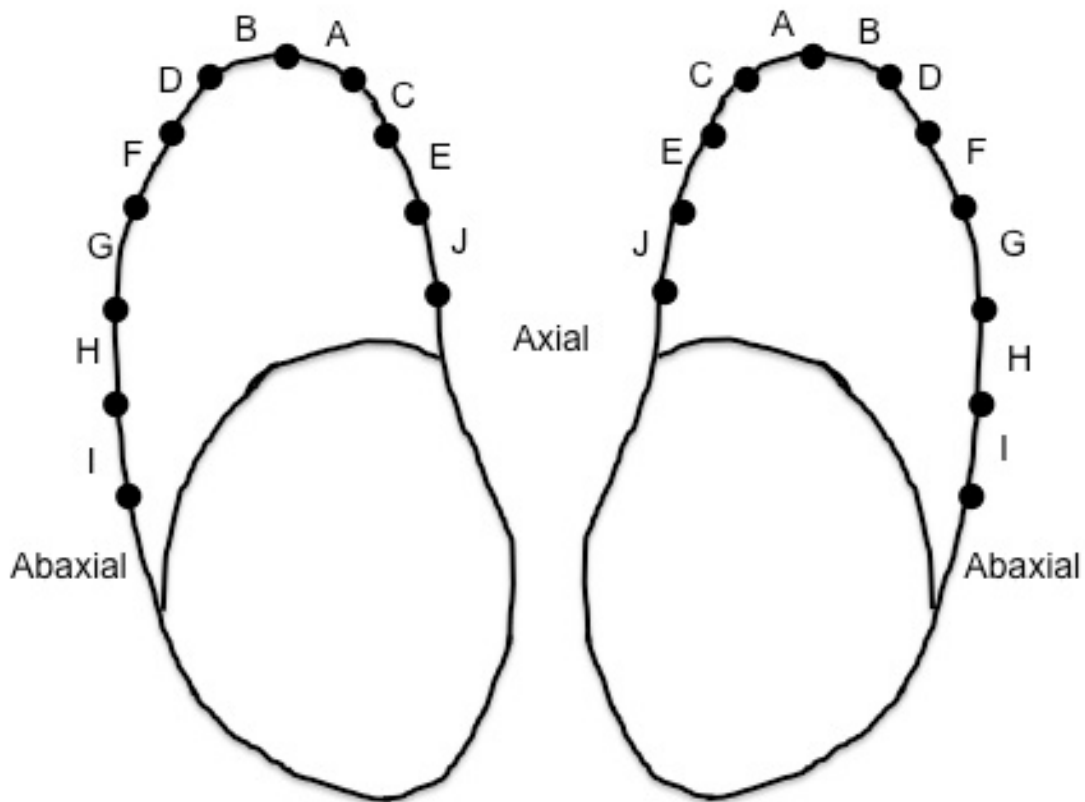


Figure 7: Schematic diagram of a hoof slice divided into zones of 25 laminae each

Table 1: Mean and standard deviation of hoof wall and sole measurements \*

	Dorsal Wall Length (Mean ± Std. Dev)	Abaxial Wall Height (Mean ± Std. Dev)	Sole Width (Mean ± Std. Dev)	Sole + Wall Length (Mean ± Std. Dev)	Ground Surface (Mean ± Std. Dev)
LF Digit 3	43.04 ± 2.82 <sup>C</sup>	30.82 ± 3.90 <sup>A</sup>	31.91 ± 3.75 <sup>A</sup>	23.89 ± 3.21 <sup>B</sup>	57.62 ± 4.54 <sup>C,D</sup>
LF Digit 4	44.21 ± 3.60 <sup>B,C</sup>	30.08 ± 4.48 <sup>A,B</sup>	32.43 ± 3.08 <sup>A</sup>	24.70 ± 2.81 <sup>B</sup>	60.82 ± 7.61 <sup>B</sup>
RF Digit 3	43.04 ± 3.15 <sup>C</sup>	28.57 ± 4.29 <sup>B,C</sup>	31.53 ± 3.48 <sup>A</sup>	23.45 ± 2.94 <sup>B</sup>	58.65 ± 5.37 <sup>B</sup>
RF Digit 4	44.45 ± 3.82 <sup>B,C</sup>	31.63 ± 4.71 <sup>A</sup>	32.24 ± 2.62 <sup>A</sup>	23.99 ± 3.03 <sup>B</sup>	60.80 ± 7.38 <sup>B,C</sup>
LR Digit 3	45.87 ± 3.80 <sup>B</sup>	28.01 ± 4.93 <sup>B,C</sup>	24.06 ± 2.45 <sup>C</sup>	21.55 ± 2.31 <sup>C</sup>	55.00 ± 5.49 <sup>D,E</sup>
LR Digit 4	48.92 ± 5.66 <sup>A</sup>	27.44 ± 5.51 <sup>C,D</sup>	29.90 ± 2.69 <sup>C</sup>	27.06 ± 4.18 <sup>A</sup>	64.75 ± 7.97 <sup>A</sup>
RR Digit 3	45.35 ± 3.81 <sup>B</sup>	25.48 ± 5.15 <sup>D</sup>	24.43 ± 3.06 <sup>B</sup>	22.44 ± 2.96 <sup>C</sup>	54.54 ± 6.64 <sup>E</sup>
RR Digit 4	49.67 ± 5.95 <sup>A</sup>	29.76 ± 5.48 <sup>A,B</sup>	30.03 ± 3.55 <sup>B</sup>	27.48 ± 4.28 <sup>A</sup>	66.67 ± 8.75 <sup>A</sup>

\*Superscript letters denote a connecting letters report. Levels not connected by the same letter are significantly different within the same column

Table 2: Mean and standard deviation of hoof wall and sole depths\*

	Dorsal Wall Depth (Mean ± Std. Dev)	Abaxial Wall Depth (Mean ± Std. Dev)	Sole Cranial Depth (Mean ± Std. Dev)	Sole Caudal Depth (Mean ± Std. Dev)	Sole Axial Depth (Mean ± Std. Dev)	Sole Abaxial Depth (Mean ± Std. Dev)
LF Digit 3	3.24 ± 0.54 <sup>C</sup>	2.77 ± 0.95 <sup>A</sup>	3.71 ± 0.94 <sup>C</sup>	3.80 ± 1.01 <sup>B,C</sup>	3.69 ± 0.97 <sup>C</sup>	3.94 ± 0.90 <sup>C,D</sup>
LF Digit 4	3.21 ± 0.51 <sup>C</sup>	2.64 ± 0.59 <sup>A,B</sup>	4.02 ± 1.04 <sup>B,C</sup>	4.07 ± 1.16 <sup>B,C</sup>	4.07 ± 1.08 <sup>B,C</sup>	4.10 ± 0.98 <sup>C,D</sup>
RF Digit 3	3.18 ± 0.58 <sup>C</sup>	2.56 ± 0.80 <sup>A,B</sup>	3.71 ± 0.94 <sup>C</sup>	3.80 ± 0.99 <sup>C</sup>	3.92 ± 1.01 <sup>B,C</sup>	3.80 ± 0.97 <sup>D</sup>
RF Digit 4	3.34 ± 0.60 <sup>B,C</sup>	2.77 ± 0.72 <sup>A</sup>	4.10 ± 1.15 <sup>A,B,C</sup>	4.30 ± 1.07 <sup>B</sup>	4.05 ± 1.03 <sup>B,C</sup>	4.39 ± 1.05 <sup>B,C</sup>
LR Digit 3	3.30 ± 0.62 <sup>C</sup>	2.38 ± 0.82 <sup>B</sup>	3.91 ± 1.17 <sup>B,C</sup>	4.15 ± 1.18 <sup>B,C</sup>	3.84 ± 1.26 <sup>C</sup>	4.15 ± 1.19 <sup>C,D</sup>
LR Digit 4	3.62 ± 0.79 <sup>A</sup>	2.52 ± 0.89 <sup>A,B</sup>	4.37 ± 1.10 <sup>A,B</sup>	4.83 ± 1.19 <sup>A</sup>	4.36 ± 1.29 <sup>A,B</sup>	4.71 ± 1.18 <sup>A,B</sup>
RR Digit 3	3.28 ± 0.56 <sup>D</sup>	2.50 ± 0.81 <sup>A,B</sup>	3.89 ± 1.18 <sup>B,C</sup>	4.04 ± 1.02 <sup>B,C</sup>	3.92 ± 1.06 <sup>B,C</sup>	4.04 ± 1.07 <sup>C,D</sup>
RR Digit 4	3.61 ± 0.71 <sup>A</sup>	2.74 ± 0.92 <sup>A</sup>	4.51 ± 1.32 <sup>A</sup>	5.11 ± 1.46 <sup>A</sup>	4.60 ± 1.26 <sup>A</sup>	5.04 ± 1.33 <sup>A</sup>

\*Superscript letters denote a connecting letters report. Levels not connected by the same letter within the same column are significantly different.

Table 3: Mean and standard deviation measurements of epidermal laminae zone width\*

	Thoracic Limb Width (Mean ± Std. Dev)	Pelvic Limb Width <sup>#</sup> (Mean ± Std. Dev)	Thoracic Limb Branching (Mean ± Std. Dev)	Pelvic Limb Branching <sup>#</sup> (Mean ± Std. Dev)
Zone A	5.28 ± 0.86 <sup>D</sup>	4.75 ± 0.71 <sup>F</sup>	1.08 ± 1.20 <sup>C</sup>	1.03 ± 1.18 <sup>D</sup>
Zone B	5.17 ± 0.84 <sup>D</sup>	4.88 ± 0.77 <sup>F</sup>	1.28 ± 1.28 <sup>B,C</sup>	1.09 ± 1.22 <sup>C,D</sup>
Zone C	5.82 ± 0.90 <sup>C</sup>	5.49 ± 0.88 <sup>F</sup>	1.47 ± 1.43 <sup>B</sup>	1.37 ± 1.47 <sup>B,C</sup>
Zone D	5.87 ± 0.83 <sup>C</sup>	5.90 ± 0.77 <sup>D</sup>	1.47 ± 1.30 <sup>B</sup>	1.68 ± 1.36 <sup>A,B</sup>
Zone E	6.80 ± 1.05 <sup>B</sup>	6.30 ± 0.95 <sup>C</sup>	2.08 ± 1.52 <sup>A</sup>	1.58 ± 1.49 <sup>A,B</sup>
Zone F	6.84 ± 0.98 <sup>B</sup>	6.75 ± 0.93 <sup>B</sup>	1.38 ± 1.21 <sup>B,C</sup>	1.71 ± 1.30 <sup>A</sup>
Zone G	7.70 ± 1.12 <sup>A</sup>	7.11 ± 1.14 <sup>A</sup>	2.10 ± 1.48 <sup>A</sup>	1.72 ± 1.16 <sup>A</sup>
Zone H	7.48 ± 1.10 <sup>A</sup>	7.19 ± 1.36 <sup>A</sup>	2.20 ± 1.75 <sup>A</sup>	1.41 ± 1.42 <sup>A,B,C,D</sup>
Zone I	7.89 ± 0.88 <sup>A</sup>		1.45 ± 1.51 <sup>A,B,C</sup>	
Zone J	7.11 ± 0.78 <sup>A,B</sup>		0.43 ± 0.79 <sup>B,C</sup>	

\*Superscript letters denote a connecting letters report. Levels not connected by the same letter within the same column are significantly different.

<sup>#</sup>Zones I and J were not present on the pelvic limbs

## CHAPTER 4

## CONCLUSIONS

This research project was conducted in order to evaluate the anatomical differences of porcine hoof capsule dimensions between the medial and lateral digits on all four limbs. Normal reference values for hoof wall measurements have not yet been completely reported, and there has been little research on the laminar junction of the porcine digit. The distal portion of all four limbs was assessed for various measurements and depths of the porcine hoof capsule. The laminar junction was also evaluated for the density of the epidermal laminae. Quantitative results were gathered and evaluated.

Results indicate that the abaxial wall, a known location for hoof wall cracks, was anatomically thinner with a less dense epidermal/dermal interconnections, possibly pre-disposing this region to lesions. The dorsal part (toe) of the hoof capsule, which bears less weight than the heel and the abaxial wall, was shown to be significantly thicker than the abaxial wall and sole. This region also had the most dense epidermal laminar zones. Dorsal wall cracks are not one of the lesions often reported. Since we found the abaxial wall to be both thinner and less dense than other regions of the hoof capsule, we proved our hypothesis to be true.

The goal of this research was to create a basis for normal reference values of measurements of the porcine hoof capsule. With the knowledge of these measurements, more accurate trimming techniques can be implemented. With the information identifying the weakest part of the hoof capsule, trimming can be



tailored toward redistributing the weight to prevent stress on the weak areas. Although hoof trimming is becoming a more accepted option for treating and preventing sow lameness, it is not a viable option for many producers. Localization of an area with an anatomical reason to be predisposed to lesions will allow a more simple and realistic pre-assessment for farm workers to check for early signs of lameness.